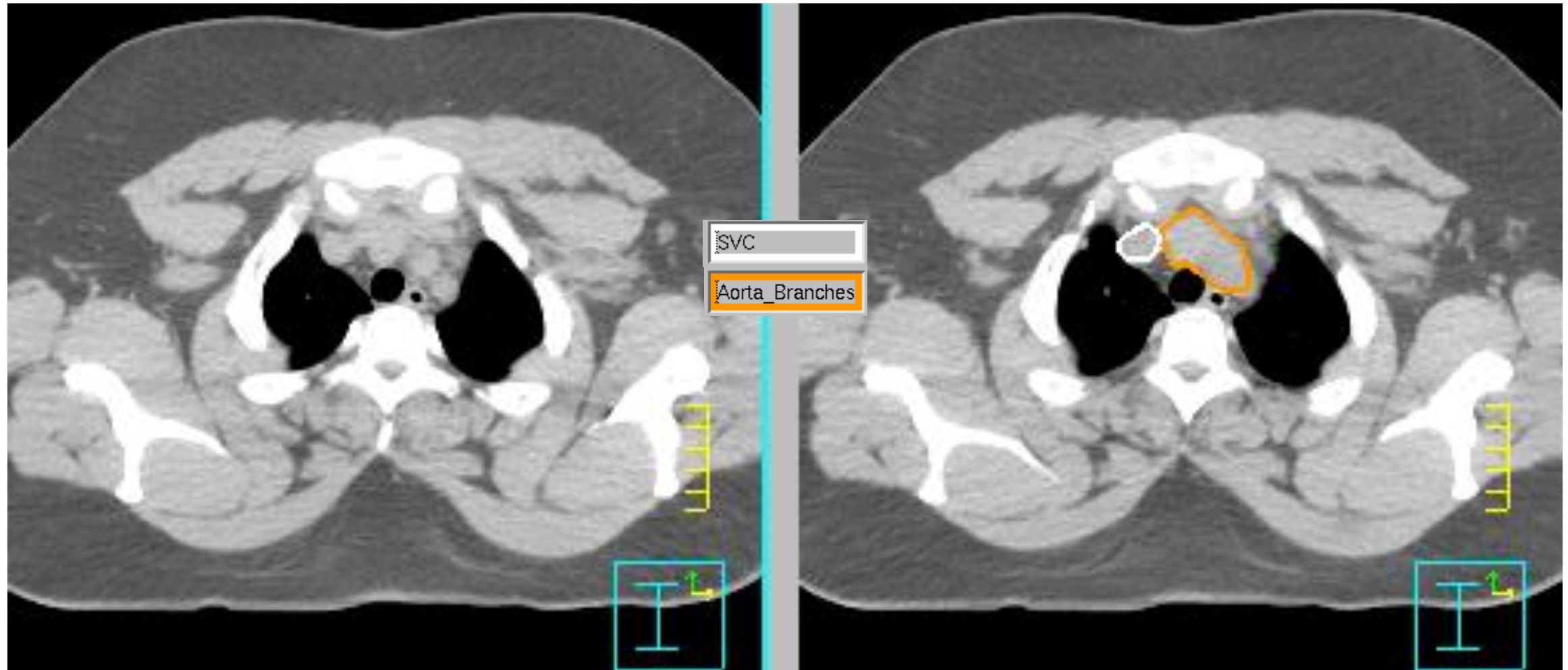
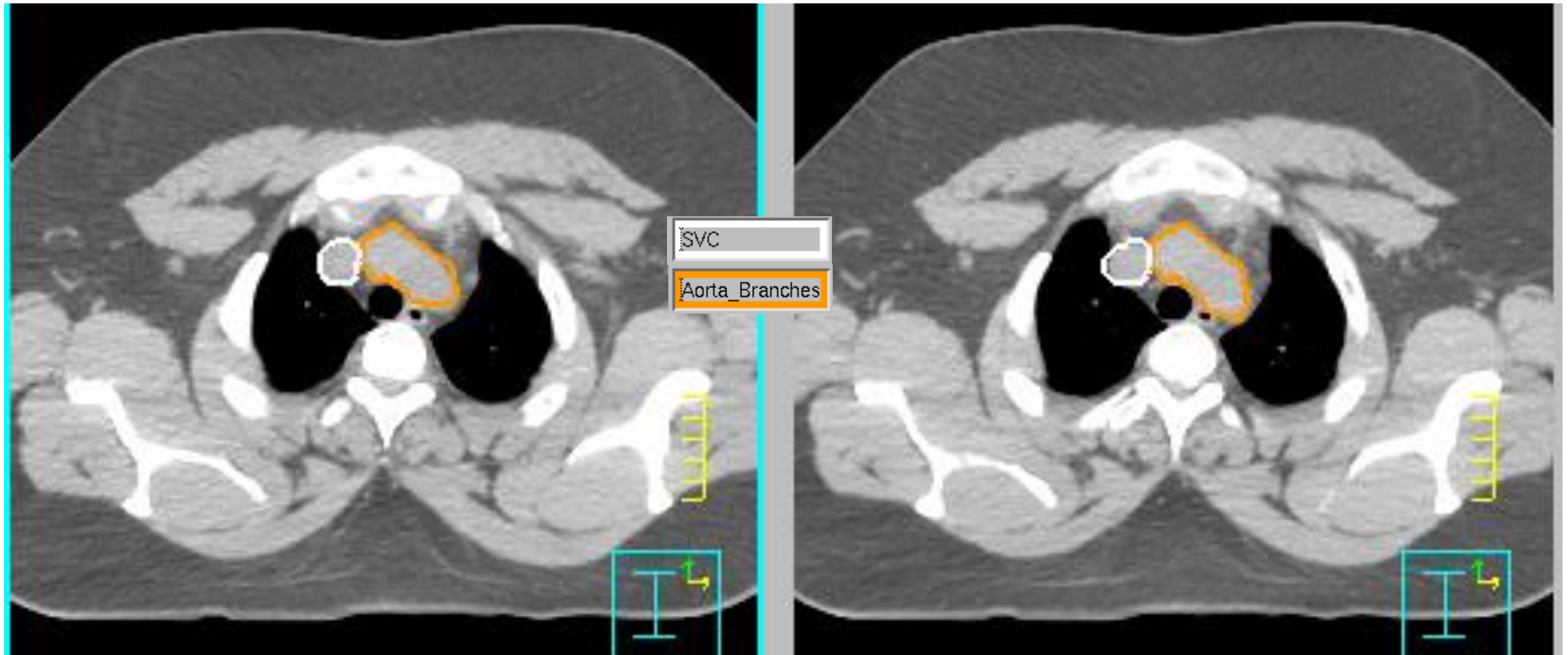


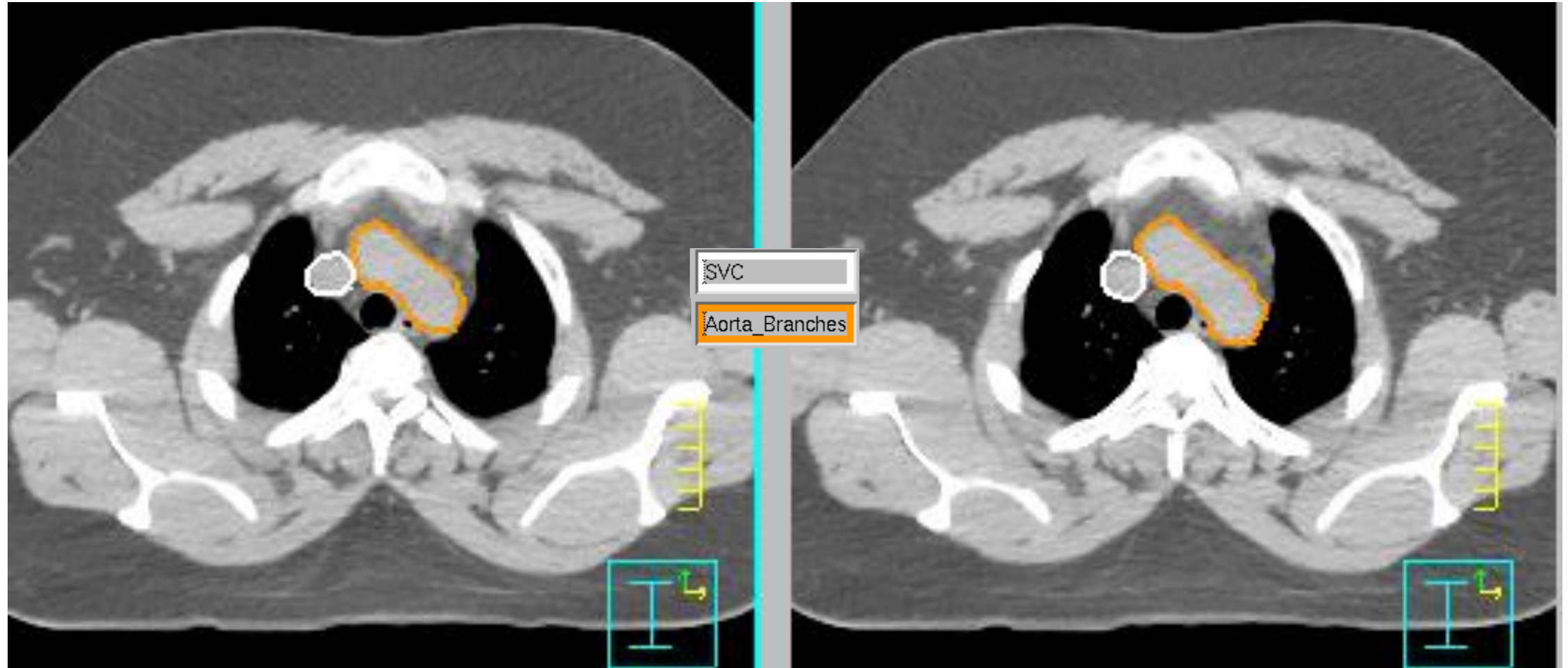
Contouring of Cardiac anatomy for a 20 year old male



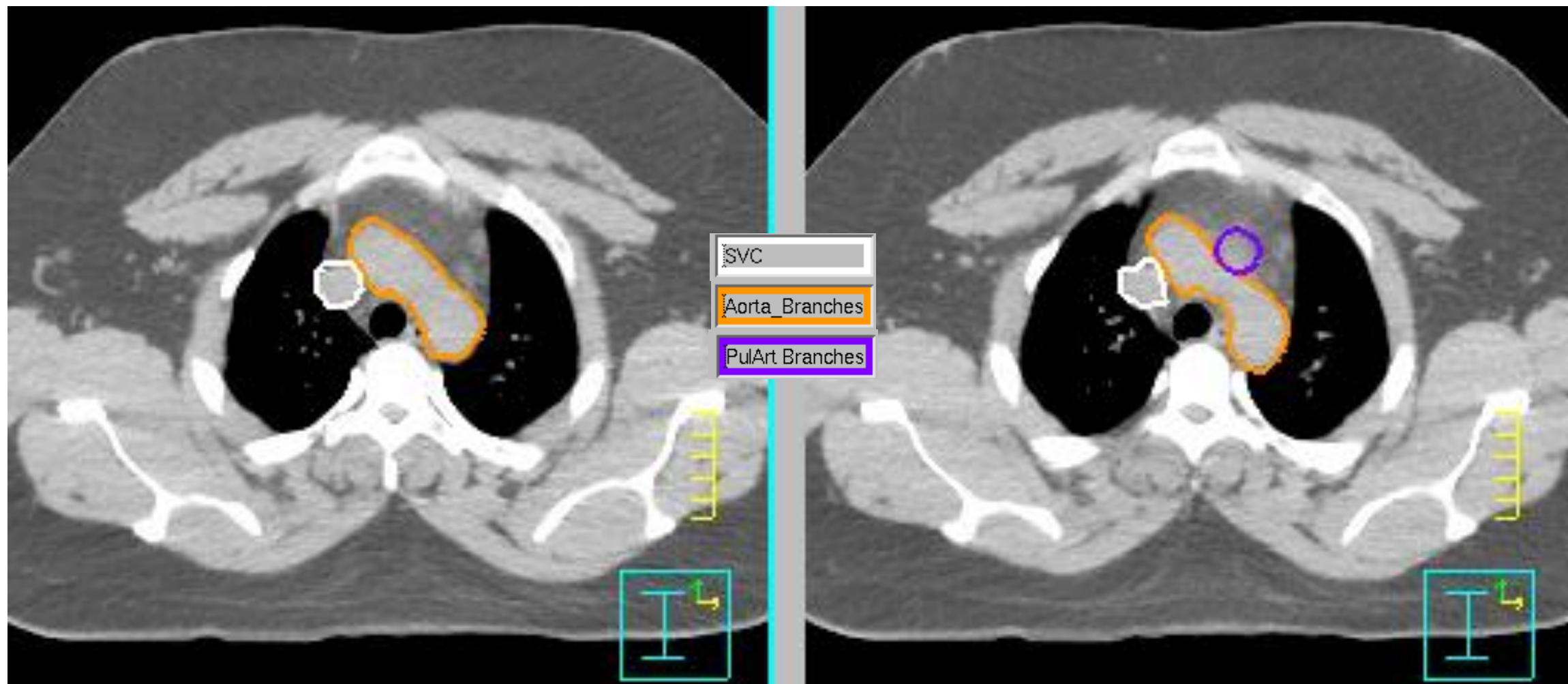
Heart and sub structures



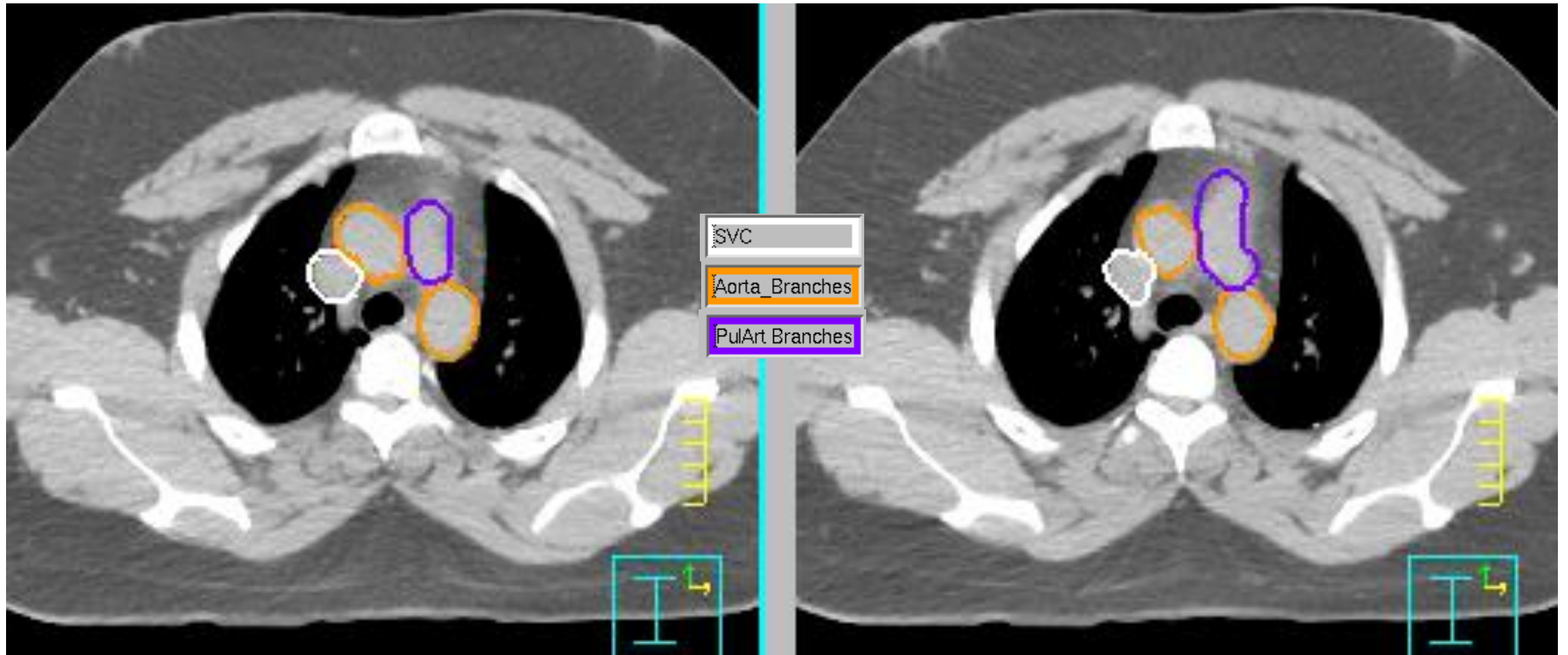
Heart and sub structures



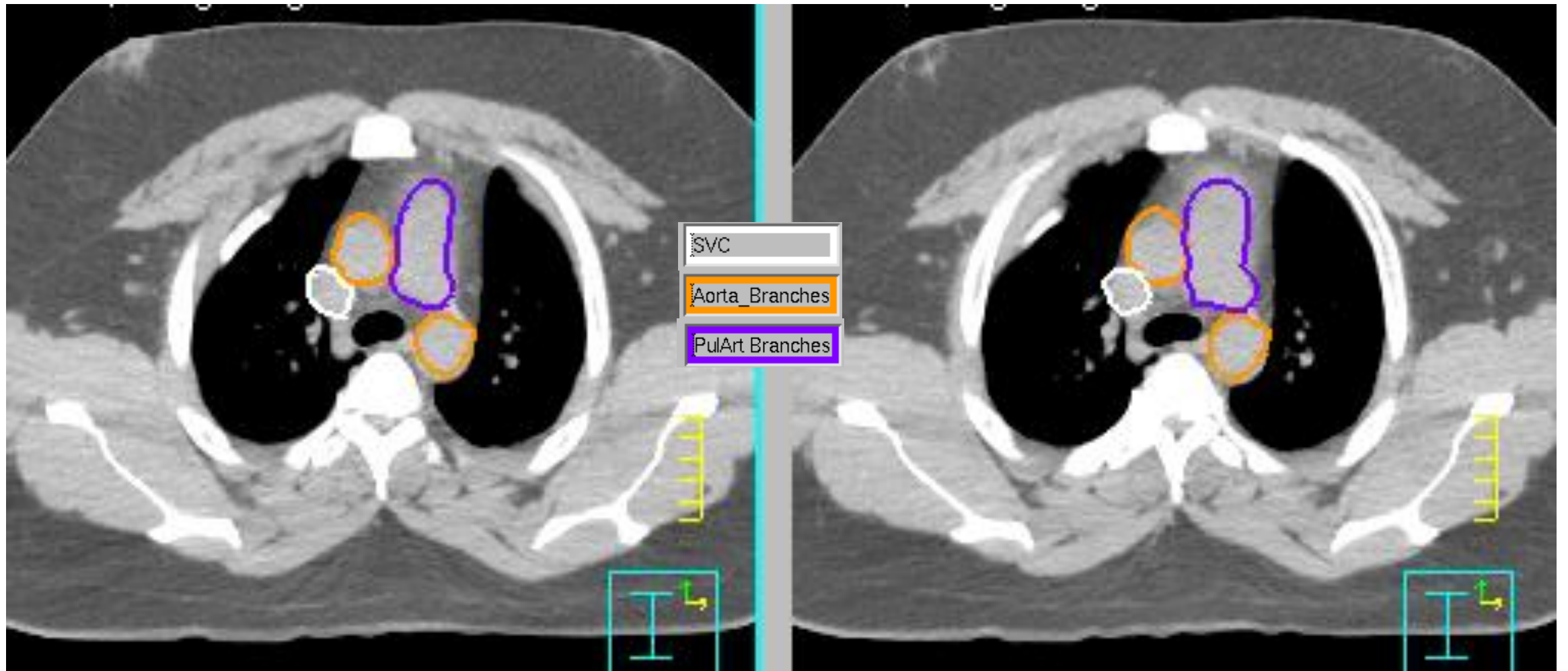
Heart and sub structures



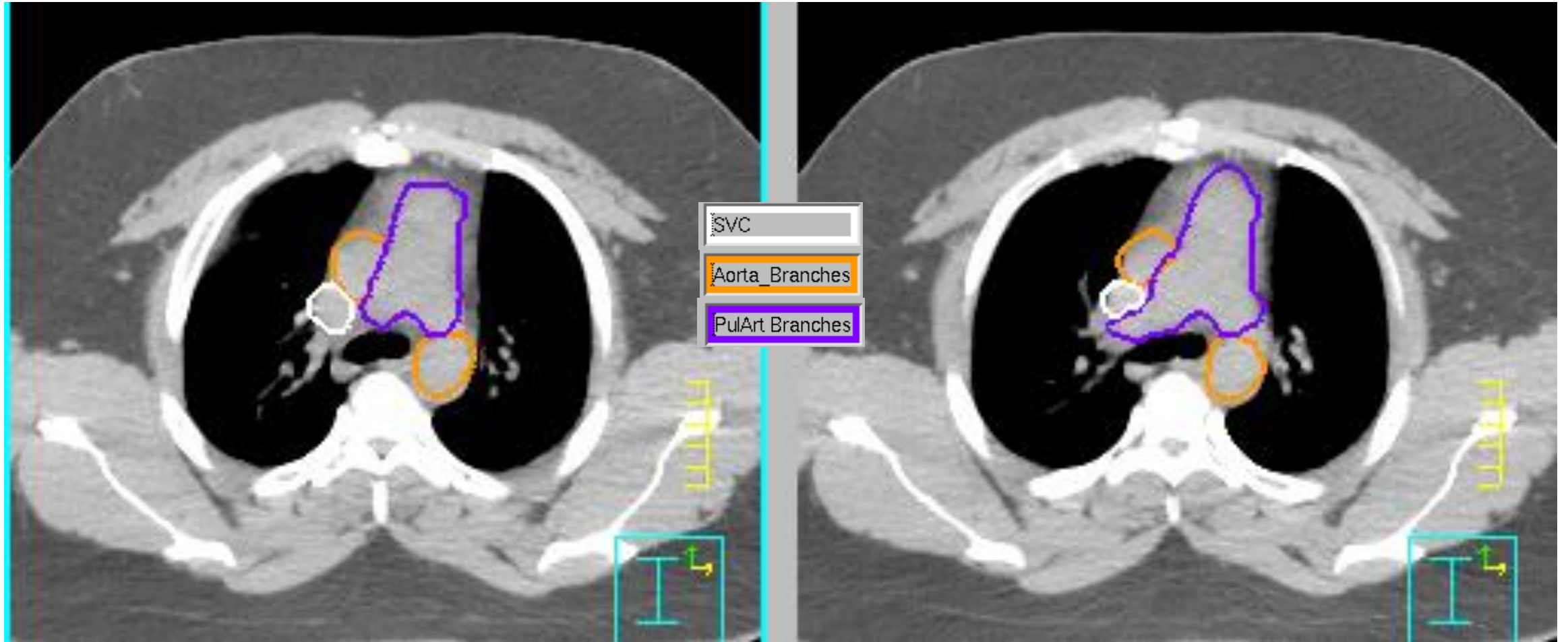
Heart and sub structures



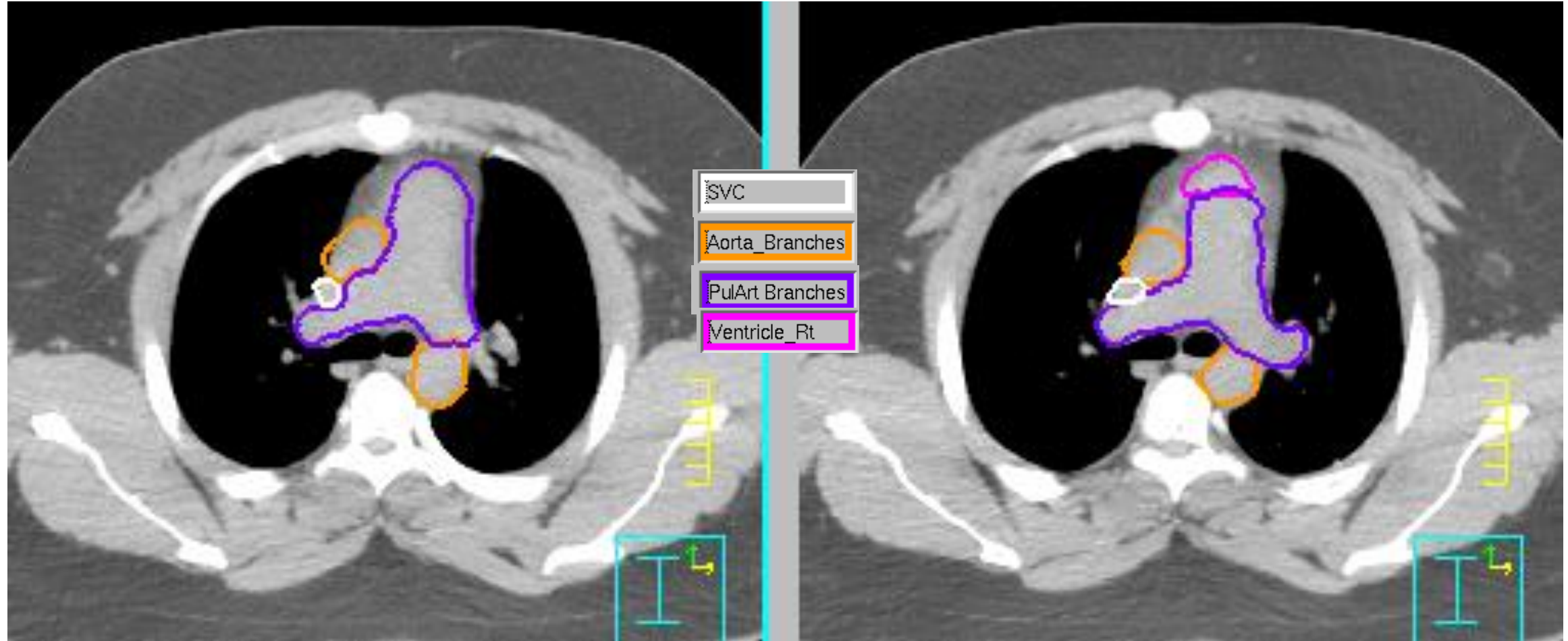
Heart and sub structures



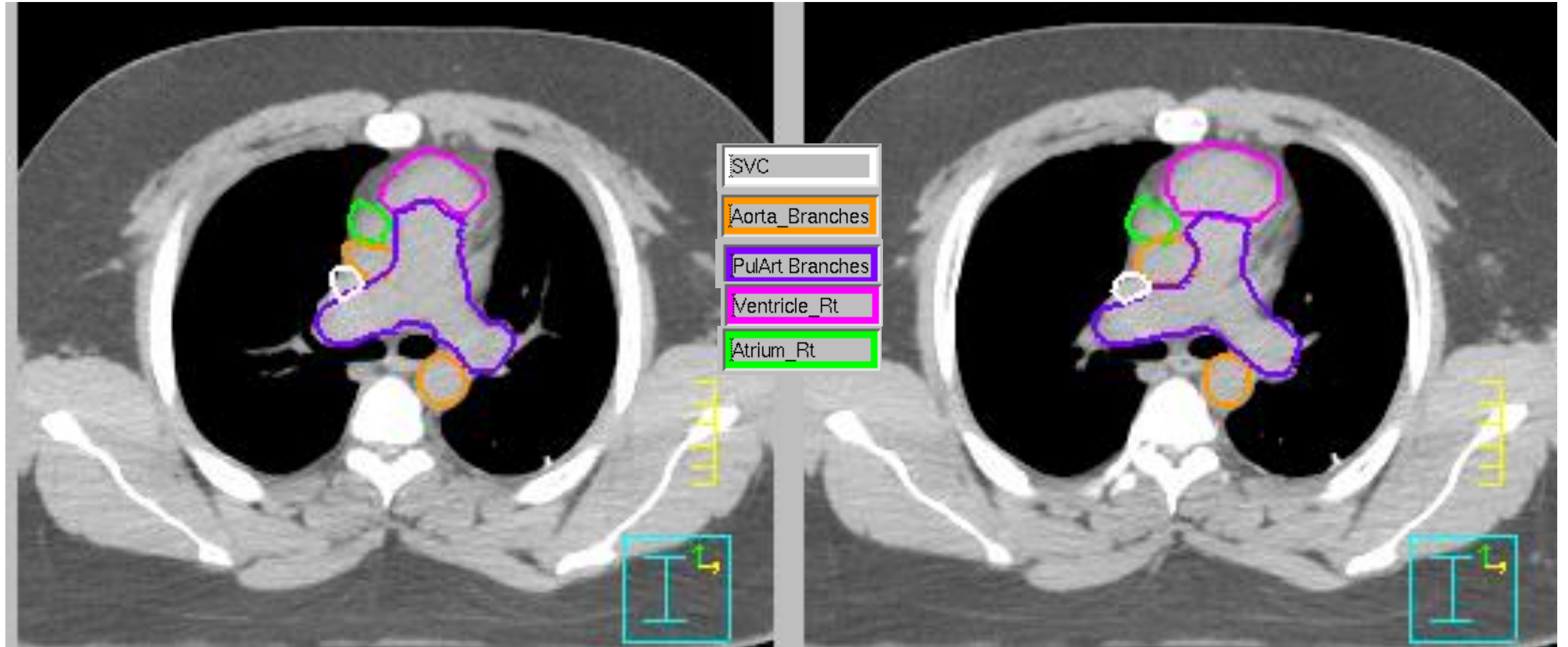
Heart and sub structures



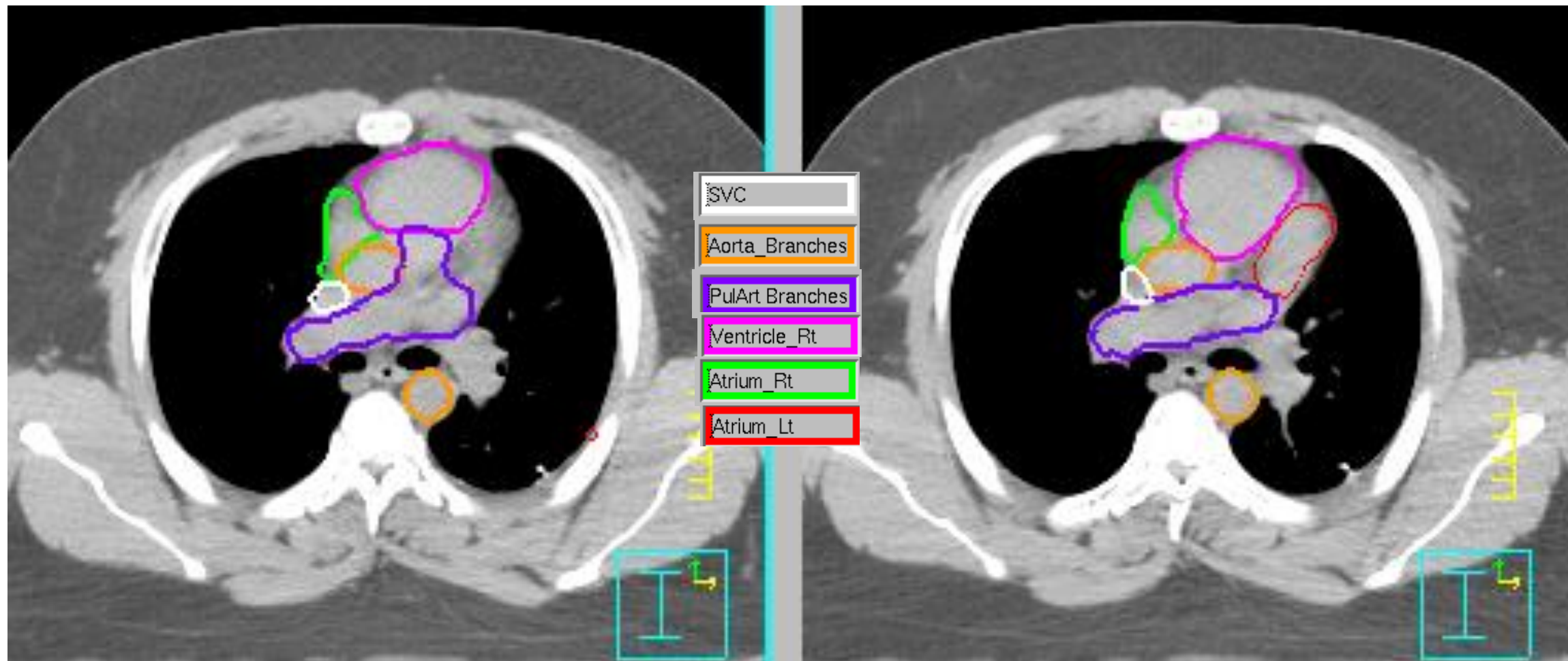
Heart and sub structures



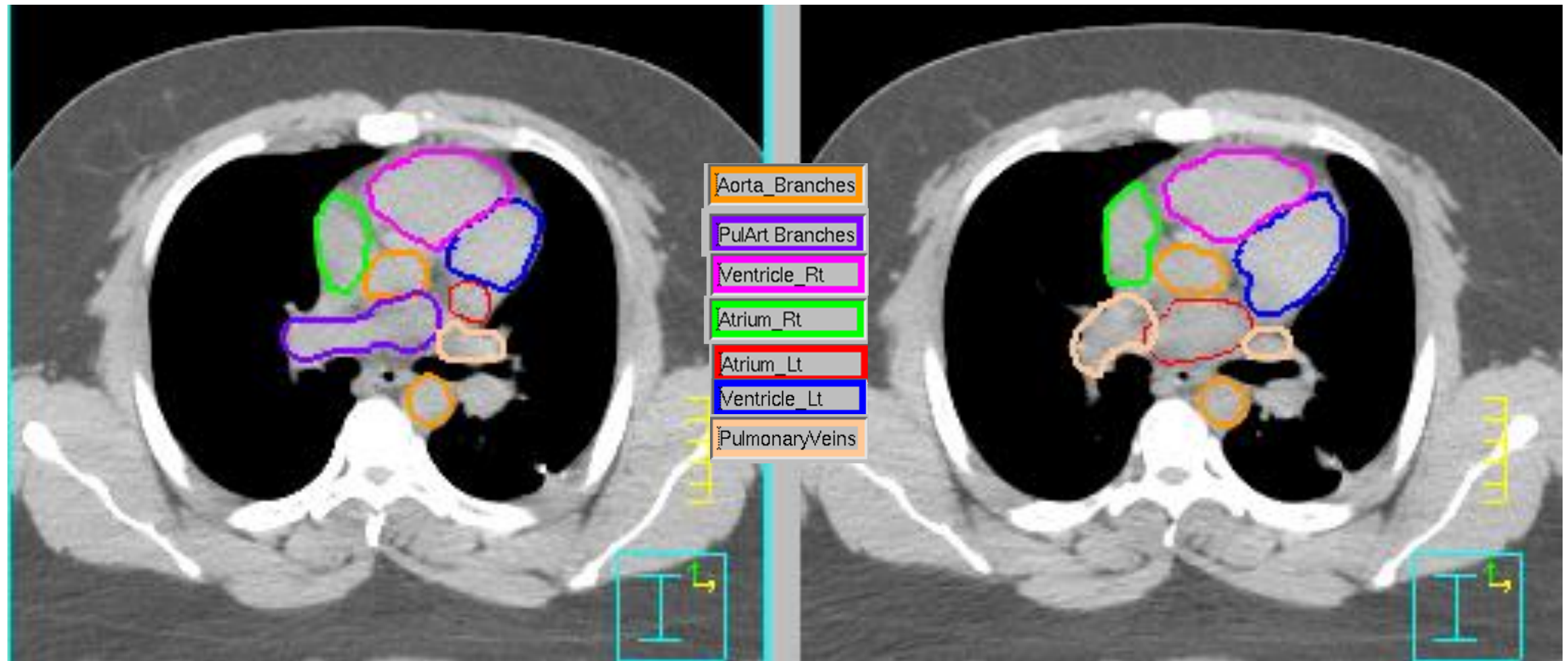
Heart and sub structures



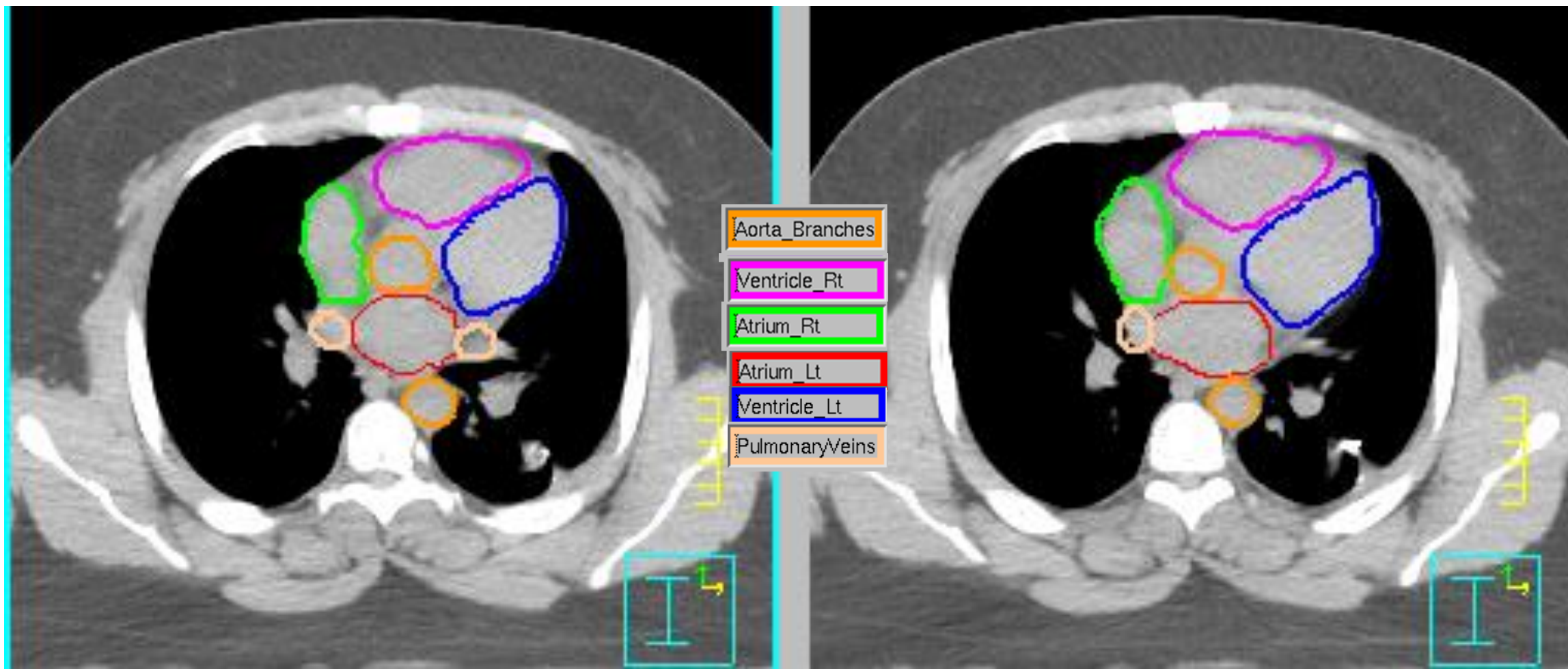
Heart and sub structures



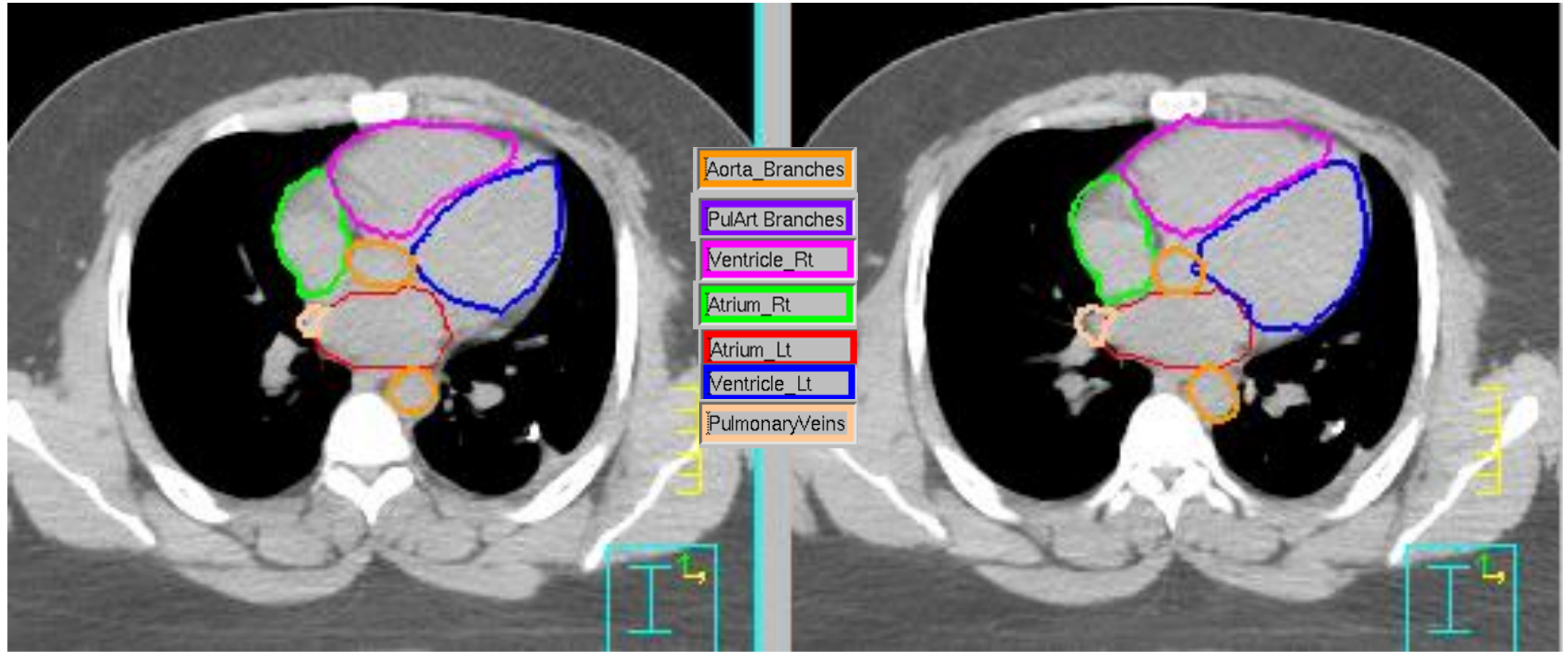
Heart and sub structures



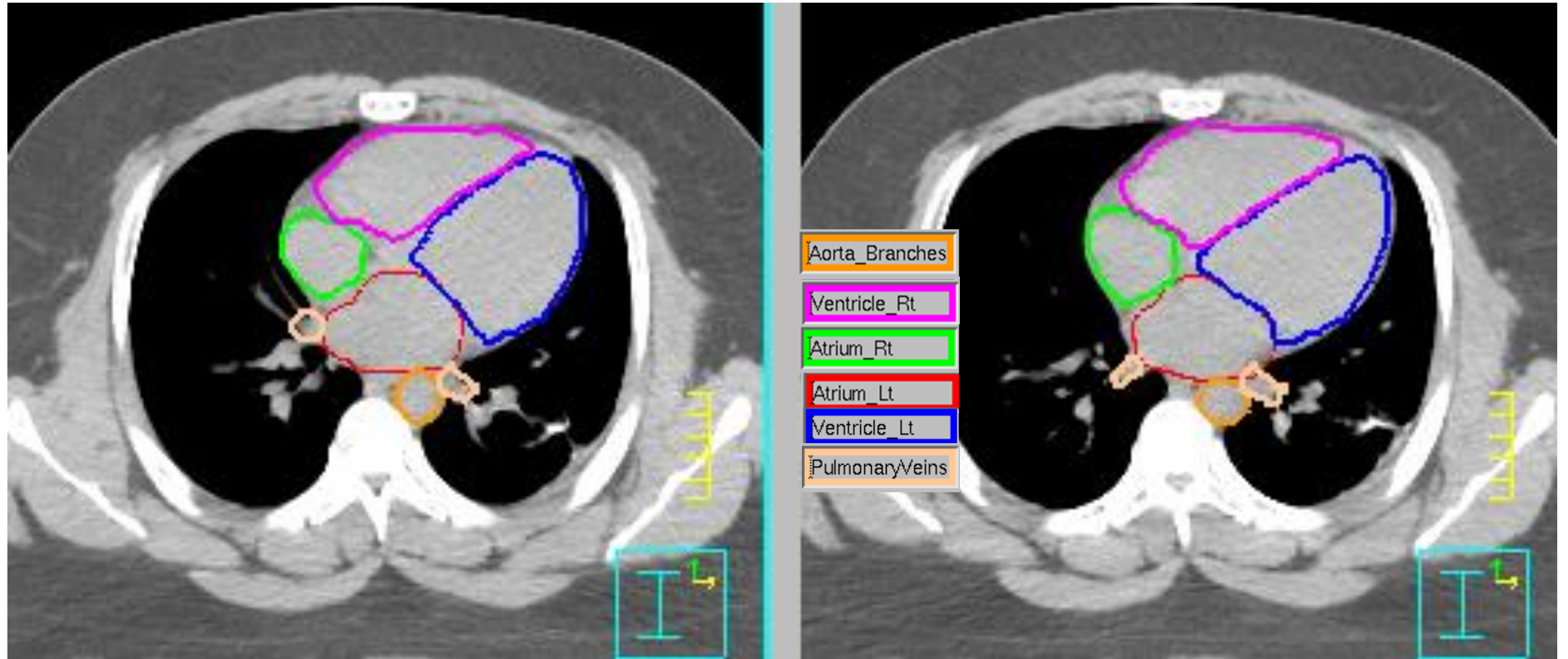
Heart and sub structures



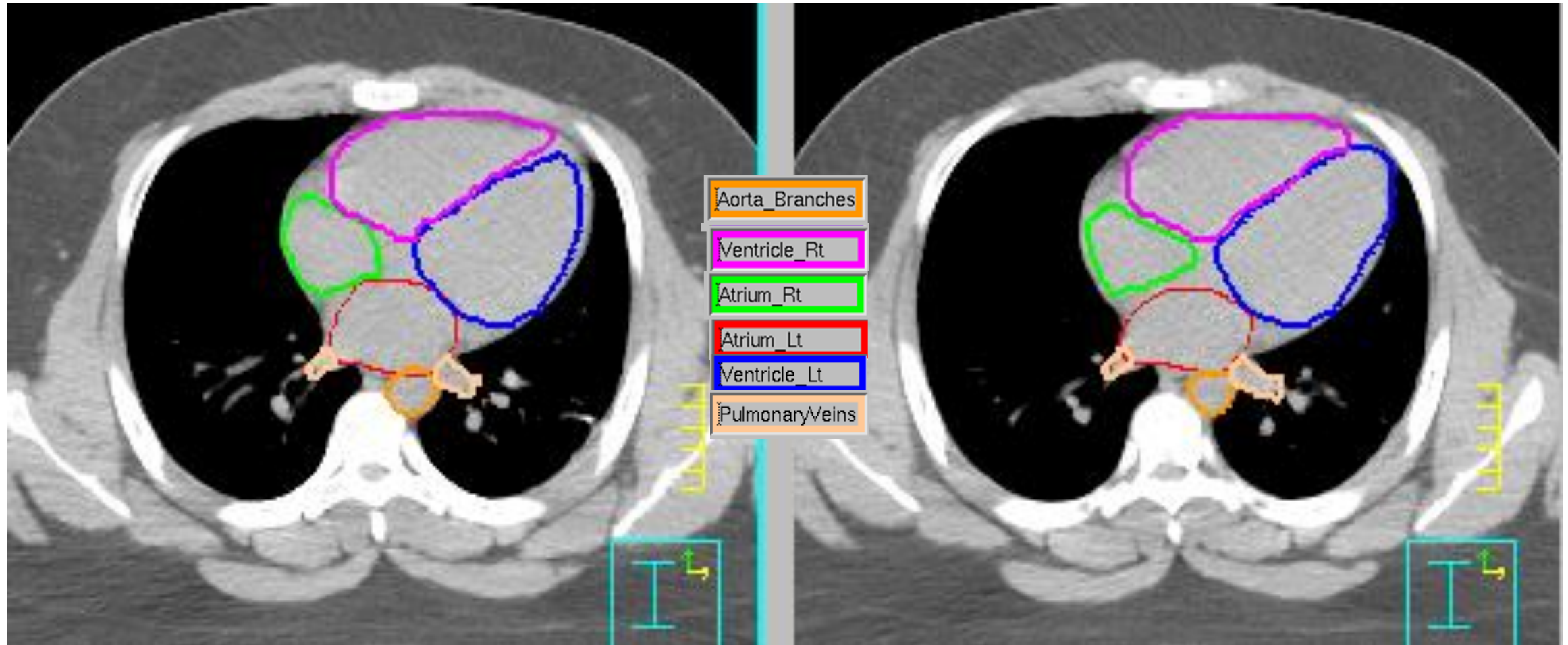
Heart and sub structures



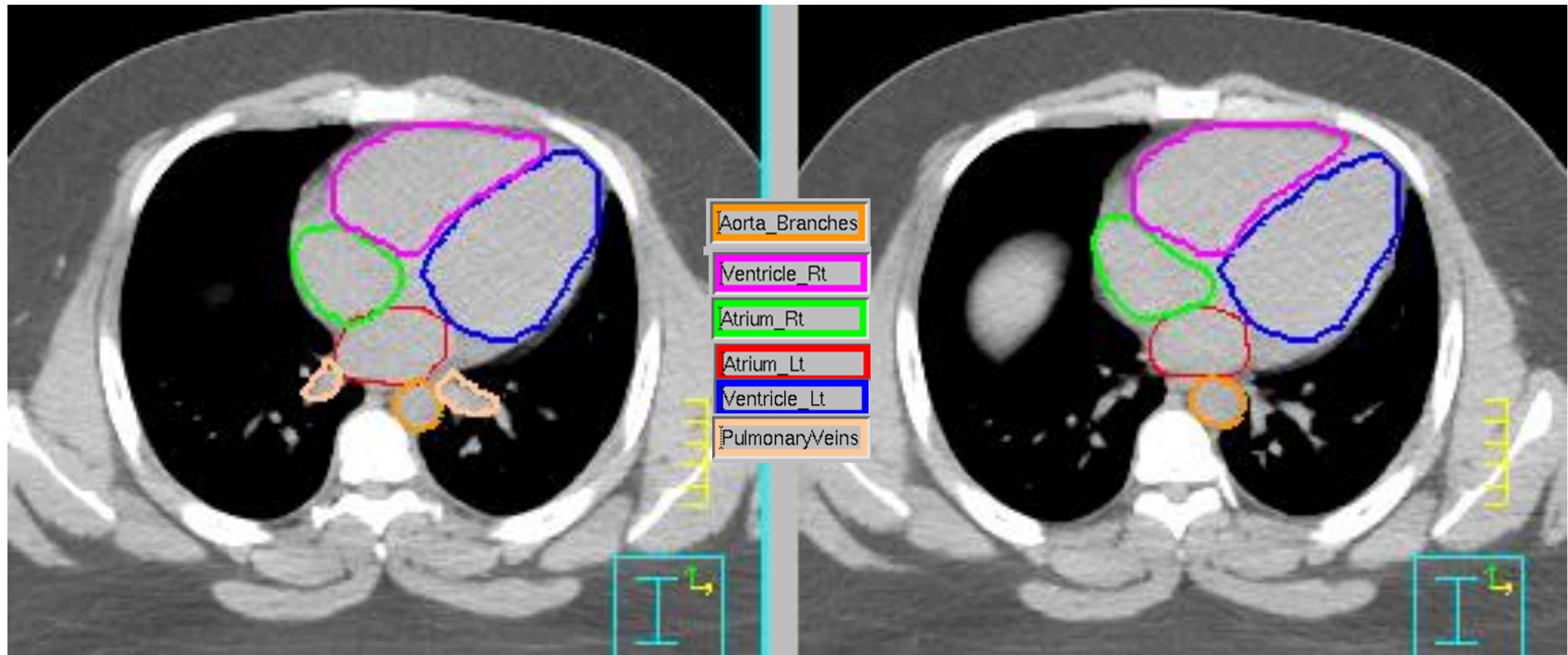
Heart and sub structures



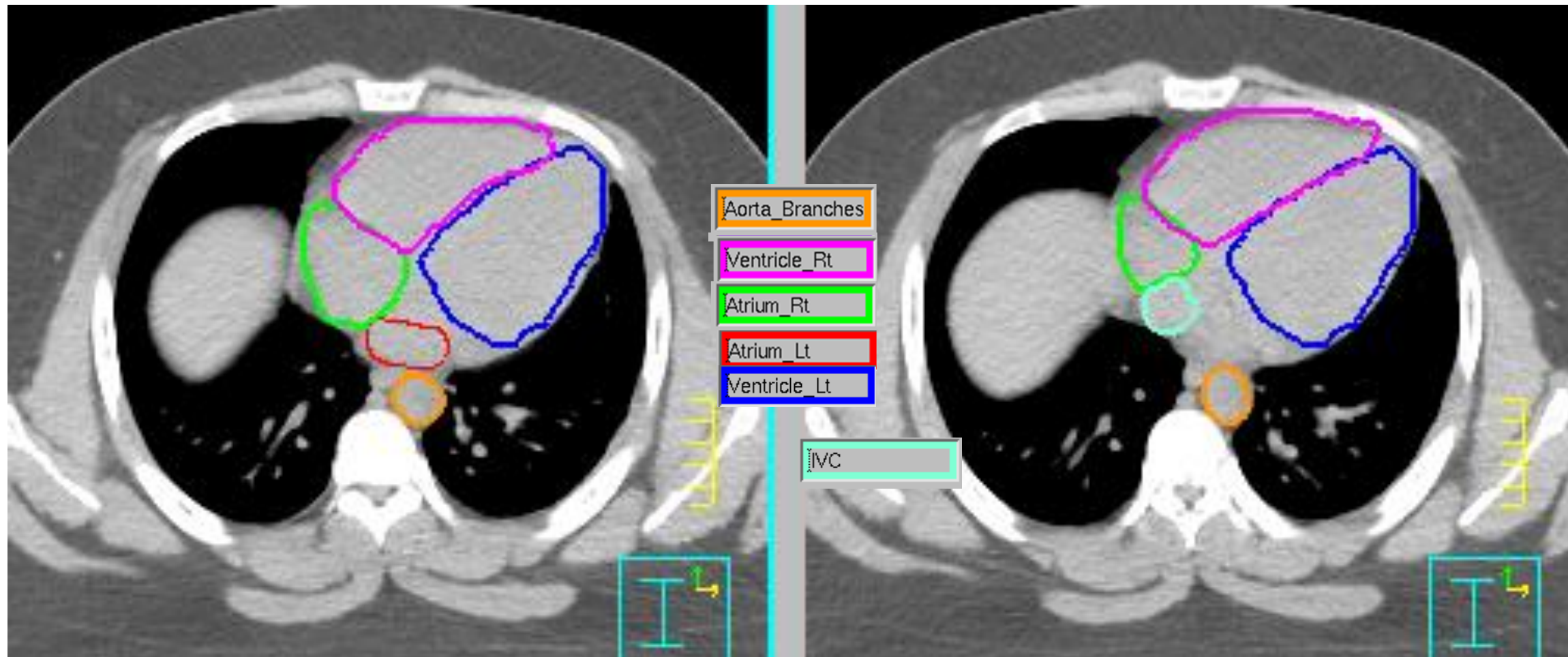
Heart and sub structures



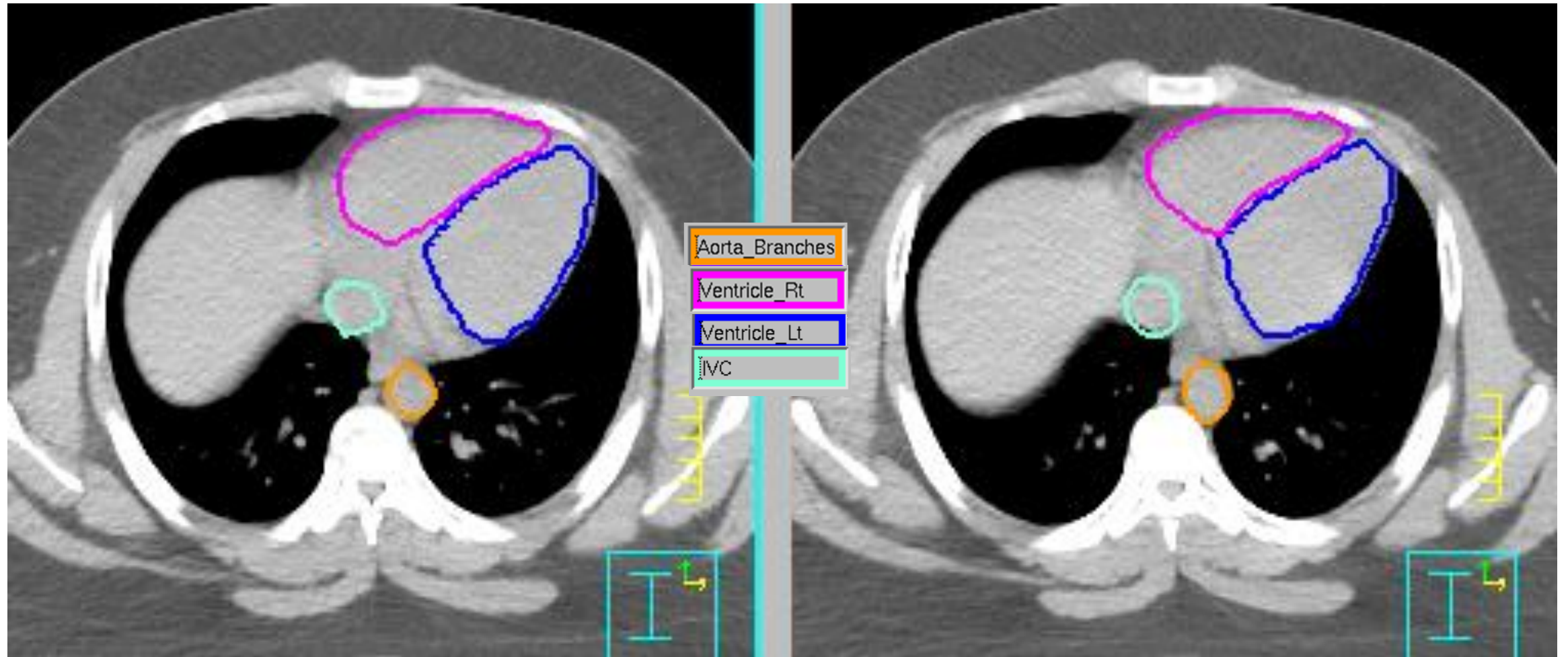
Heart and sub structures



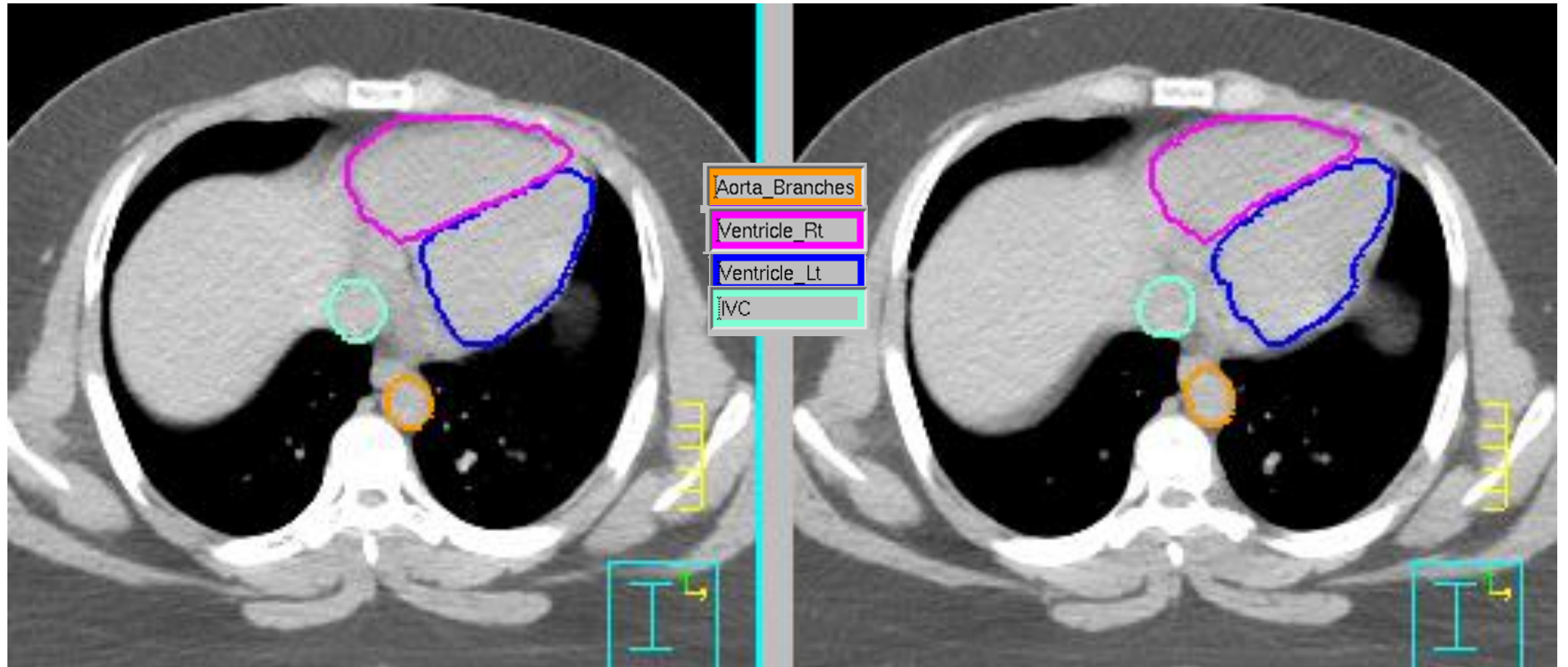
Heart and sub structures



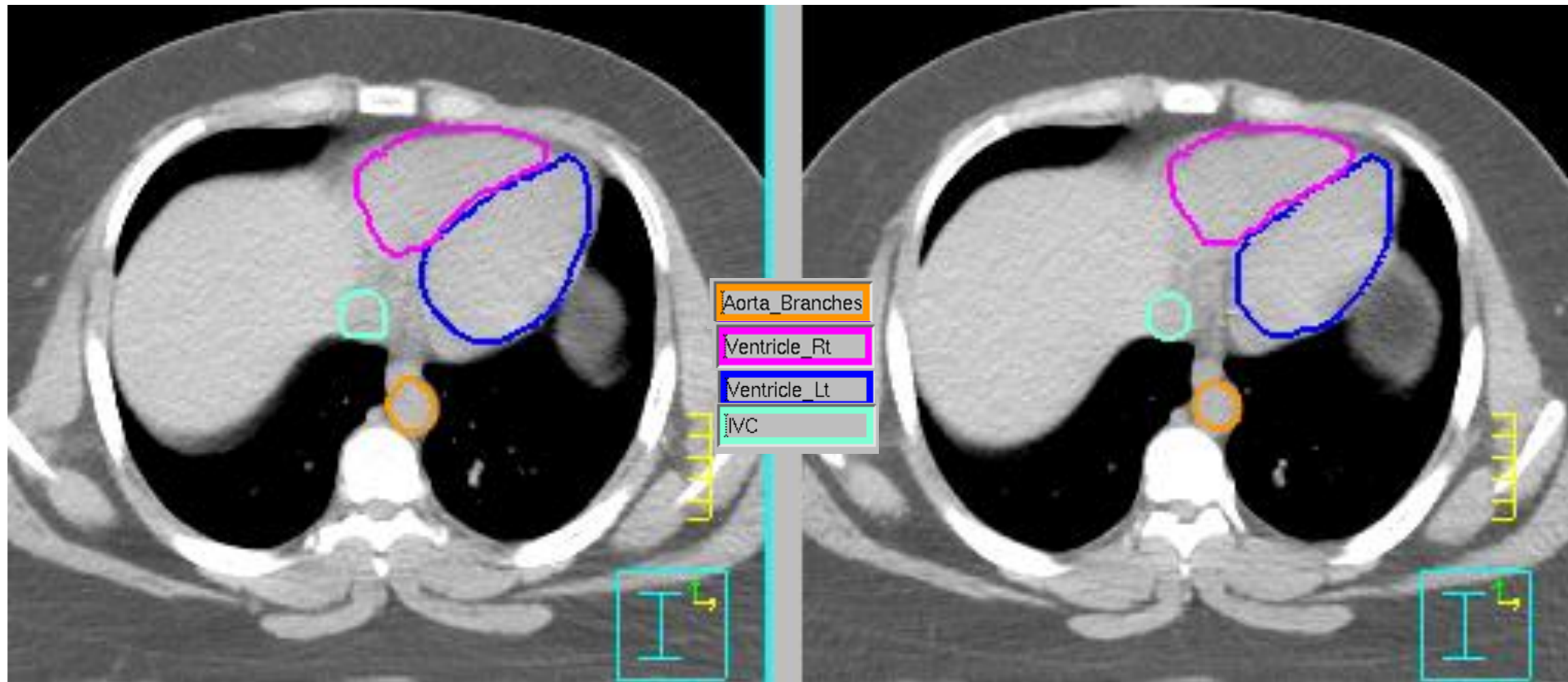
Heart and sub structures



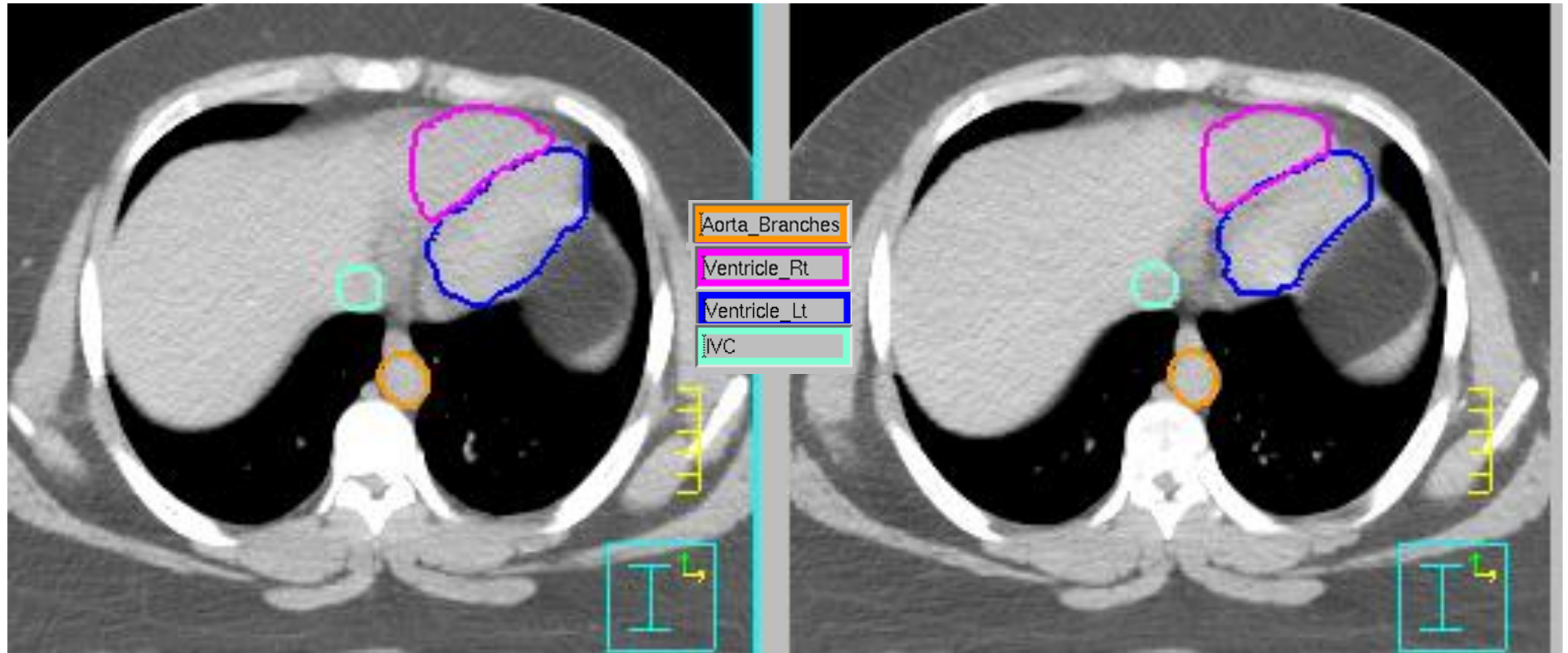
Heart and sub structures



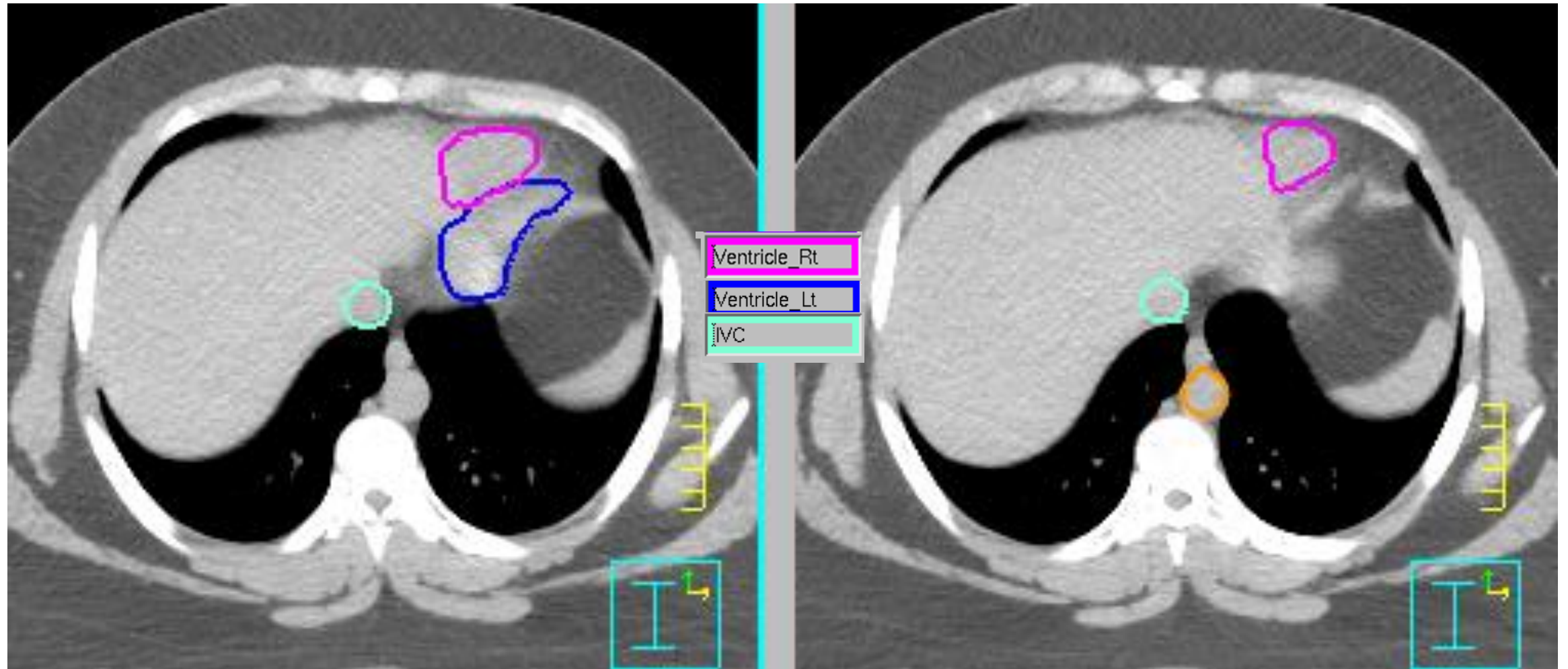
Heart and sub structures



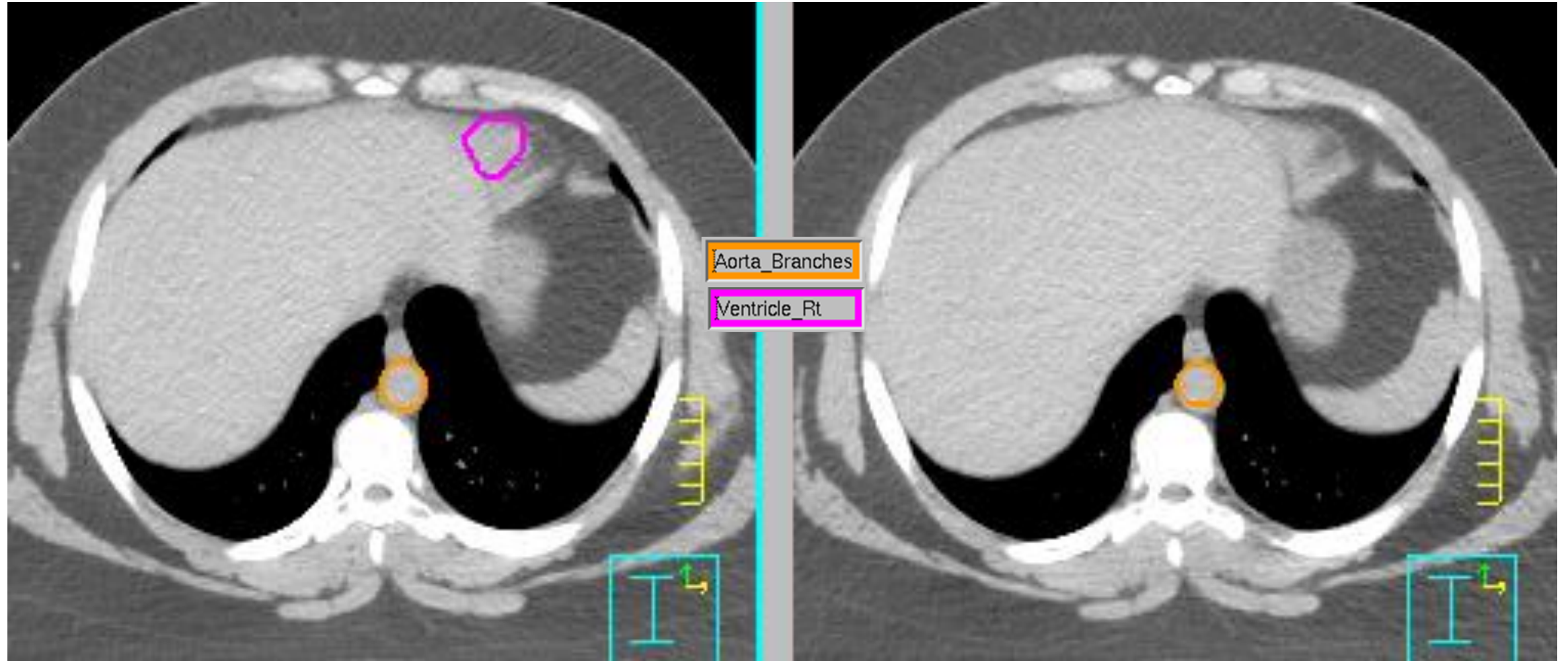
Heart and sub structures



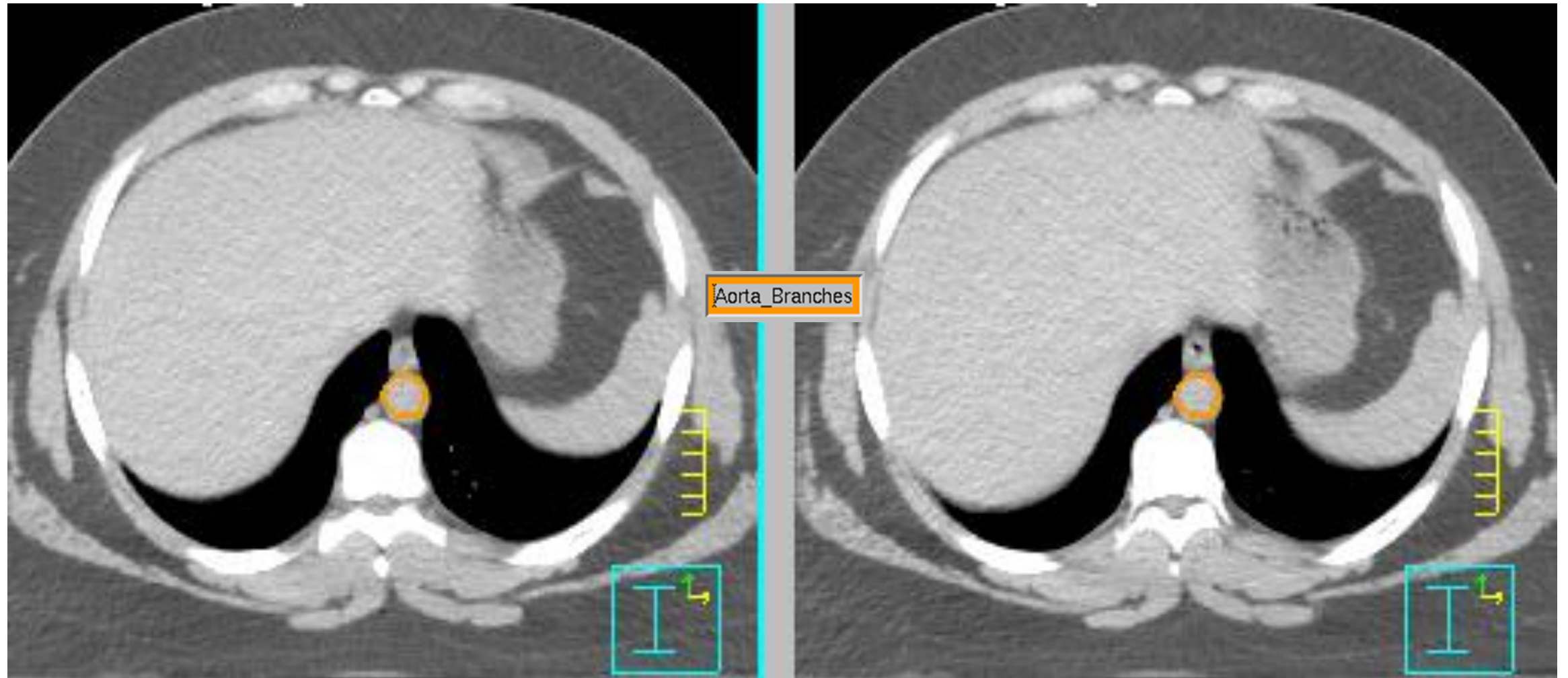
Heart and sub structures



Heart and sub structures



Heart and sub structures



Heart and sub structures

